

## Idiopathic CD4 Lymphocytopenia with Cryptococcal Meningoencephalitis: A Rare Case Report

Nitya Nand\*, Deepak Jain\*\*, Raghunandan SK\*\*\*, Pavan Kumar YM\*\*\*, Preeti Verma\*\*\*

### Abstract

*Cryptococcal infection is usually considered as a disease of immunocompromised state and is relatively rare in the absence of impaired immunity. However in the recent years apart from patients with Human immunodeficiency virus (HIV) infections/Acquired immunodeficiency syndrome (AIDS) there are case reports of patients with AIDS like symptoms without HIV infection which show severe CD4 T lymphocyte depletion and predispose these patients to severe opportunistic infections similar to those found in patients with HIV/AIDS. Such cases have been termed as Idiopathic CD4 lymphocytopenia. Here we report a rare case of cryptococcal meningoencephalitis occurring in an immunocompetent patient, who on further evaluation was diagnosed with this rare syndrome.*

### Introduction

Cryptococcal meningitis is an important opportunistic infection diagnosed in patients with Human immunodeficiency virus (HIV) infection/Acquired immunodeficiency syndrome (AIDS), with an incidence ranging from 10% to 30%<sup>1</sup>. Severe CD4 T-cell depletion in HIV/AIDS patients, predispose them to cryptococcal infections. Presence of cryptococcal meningitis in immunocompetent hosts is rarely described. There are scanty case reports of presence of cryptococcal meningitis in patients with decreased CD4 cells and this clinical entity with depletion of CD4 cells without an HIV infection is known as idiopathic CD4 lymphocytopenia<sup>2</sup>. The clinical spectrum of this rare syndrome ranges from asymptomatic laboratory abnormality to life-threatening opportunistic infections such as cryptococcal meningitis, *pneumocystis jirovecii* pneumonia, pulmonary and extra pulmonary histoplasmosis, atypical mycobacterial pneumonia and cytomegalovirus pneumonia. Here we present a rare case of cryptococcal meningoencephalitis occurring in an immunocompetent patient, who was later diagnosed with this rare syndrome.

### Case report

A 62-year-old male government official by occupation, non-alcoholic, non-smoker, presented with complaints of fever for 15 days and altered sensorium for 1 day. Patient had no history of cough with expectoration, loose stools or vomiting, headache, seizures, jaundice, any trauma to head or weakness of any part of the body. Patient had no past history of diabetes mellitus, tuberculosis, bronchial asthma, ischaemic heart disease or any other chronic disease or

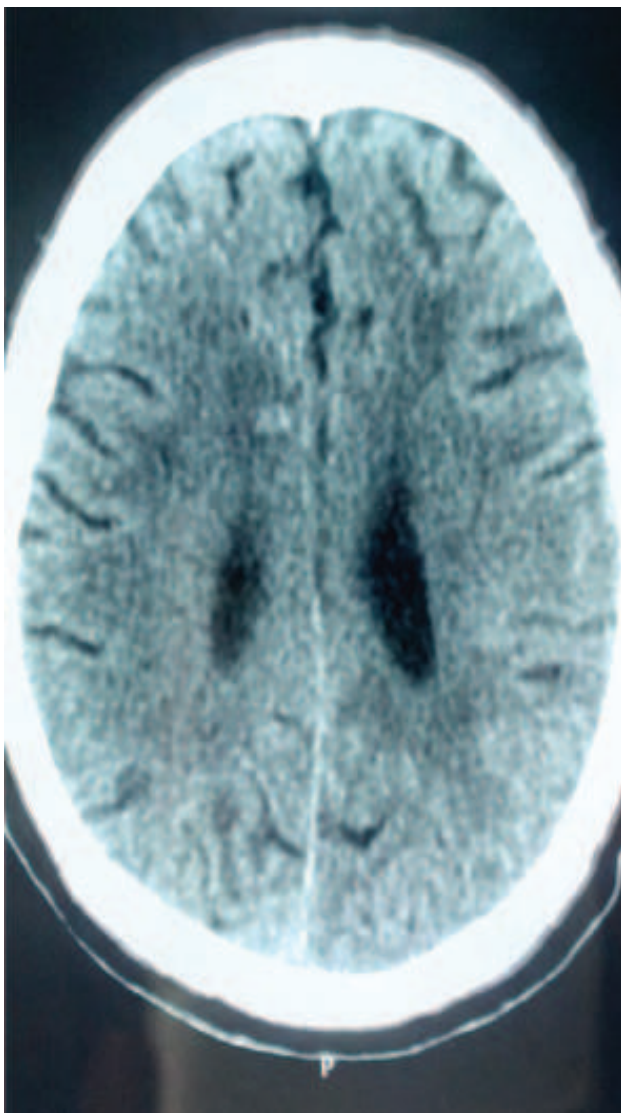
malignancy. There was no exposure to pet animals, including pigeons. On examination, patient was haemodynamically stable with a BP of 114/82 mmHg, pulse rate of 82/min, regular in character. He had mild pallor but there was no cyanosis, icterus or lymphadenopathy. Cardiovascular, respiratory and abdominal examinations were essentially normal. On neurological examination he had altered sensorium with a GCS of 6/15. Patient had neck rigidity and his plantar reflexes were bilaterally extensor.

On investigations, complete haemogram showed an Hb of 12.5 g/dl, total leucocyte count was 7,000/cumm with differential leucocyte count of 66% neutrophils, 28% lymphocytes, 4% monocytes and 2% eosinophils and, platelet count of 1.9 lac/cumm. Random blood sugar, thyroid profile, liver function tests and renal function tests were within normal limits. Peripheral blood smear for malarial parasites and widal test were negative. Urine and blood cultures were negative. IgM antibodies against dengue, typhoid, leptospira, scrub typhus, Human immunodeficiency virus, hepatitis B and C were also negative. Chest X-ray, electrocardiogram, ultrasonography of the abdomen were within normal limits. CSF examination was done which revealed increased proteins of 244 mg/dl, sugar 55 mg/dl (corresponding blood sugar: 122 mg/dl), total leucocyte count of 164 cells/cumm with 20% neutrophils and 80% lymphocytes and no organisms detected on gram staining. ADA in CSF was slightly raised with a value of 13.8 u/l (normal value < 10 u/l) erythrocyte sedimentation rate, C-reactive protein and Antinuclear antibody (ANA) were within normal limits. NCCT head showed a ring configuration lesion in left frontal region in the subcortical location which was suggestive of inflammatory granuloma

\*Senior Professor and Head, \*\*Associate Professor, \*\*\*Resident, Department of Medicine, Pandit B.D. Sharma University of Health Sciences, Rohtak - 124 001, Haryana.

Corresponding Author: Dr Deepak Jain, Associate Professor, Department of Medicine, Pandit B.D. Sharma University of Health Sciences, Rohtak - 124 001, Haryana. Phone:9416147887, E-mail:jaindeepakdr@gmail.com.

or tuberculoma (Fig. 1). In view of the above findings, a presumptive diagnosis of tubercular meningitis was considered and the patient was started on empirical IV antibiotics, antitubercular therapy and dexamethasone. But patient failed to show any improvement in sensorium in the next 5 to 6 days. A repeat CSF examination was done which showed similar picture as of the previous report with raised proteins and leucocytosis. However, this time PCR (Gene Xpert) for tuberculosis was sent which was negative, cryptococcal antigen was positive (by latex agglutination methods) and fungal capsules were identified by India ink preparation. MRI brain with contrast imaging showed multiple T2/FLAIR hypointense lesions revealing ring enhancement on contrast imaging in B/L fronto

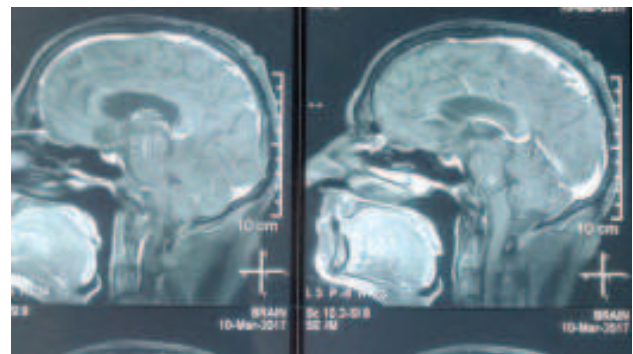


**Fig. 1:** NCCT head showing ring configuration lesions in left frontal region in the subcortical location suggestive of inflammatory granuloma or tuberculoma.

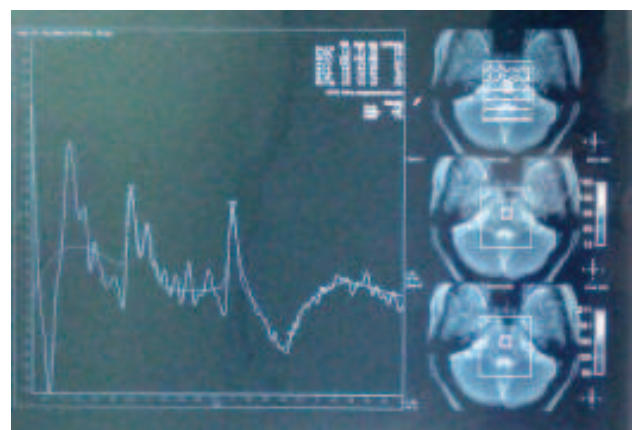
parietooccipital, B/L cerebellar and brain stem areas suggestive of neurocysticercosis, tuberculoma, or cryptococcoma (Fig. 2). To further narrow down the differentials, serological testing to demonstrate antibodies to cysticerci in serum by enzyme-linked immuno electro transfer blot for neurocysticercosis was done, which was negative. Further as MR spectroscopy did not show any evidence of lipid, or lactate peak, possibility of tuberculoma and neurocysticercosis were completely ruled-out (Fig. 3).

In view of the CSF findings with positive antigen test and MRI and MR spectroscopy findings, a diagnosis of cryptococcal meningoencephalitis was established and patient was started with Inj amphotericin B and flucytosine, patient responded well to the treatment and was fully conscious and oriented by 6th day of the therapy. After 2 weeks of therapy patient was shifted on tab fluconazole 400 mg OD.

As our patient was immunologically competent, the occurrence of cryptococcal meningoencephalitis we further investigated the immune status of the patient. Accordingly



**Fig. 2:** MRI brain with contrast image showing multiple T2/FLAIR hypointense lesions revealing ring enhancement on contrast imaging in B/L fronto parietooccipital, B/L cerebellar and brain stem areas suggestive of neurocysticercosis/tuberculomas/cryptococcomas.



**Fig. 3:** MR spectroscopy showing choline and N-Acetyl aspartate peaks and no evidence of lipid or lactate peaks.

the HIV status was reconfirmed by specific tests such as ELISA and Western Blot, which were also found to be negative. As a further step of the investigation, we obtained the CD4 counts of the patient which were found to be markedly reduced with an absolute value of 233/ul and 236/ul one week apart. Immunoglobulin A, G and M were within normal limits. Bone marrow and PET scan did not show any evidence of malignancy. CD4+ counts repeated after 6 weeks was again found to be 272/ul. Hence our patient was diagnosed with the rare syndrome of idiopathic CD4 lymphocytopenia, complicated with cryptococcal meningoencephalitis. Presently patient is doing well on regular follow-up and is on tab fluconazole 400 mg OD.

**Table I: Opportunistic infections in ICL patients.**

Category	Infectious agent
Bacteria	<i>Mycobacterium avium intracellulare</i> .
	<i>Mycobacterium tuberculosis</i>
	<i>Mycobacterium mucogenicum</i>
	<i>Mycobacterium kansasii</i>
	<i>Salmonella typhimurium</i>
Fungus	<i>Cryptococcus neoformans</i>
	<i>Pneumocystis jirovecii</i>
	<i>Candida albicans</i>
	<i>Histoplasma capsulatum</i>
Virus	Cytomegalovirus
	Varicella zoster virus
	Human herpes virus-8
	HPV
	JC virus
Parasite	Toxoplasmosis
Protozoan	Leishmaniasis

## Discussion

Cryptococcal infection is usually considered as a disease of immunocompromised state and is relatively rare in the absence of impaired immunity. Individuals at high-risk for disease due to *C. neoformans* include patients with hematologic malignancies, recipients of solid organ transplants who require ongoing immunosuppressive therapy, persons whose medical condition necessitate glucocorticoid therapy and patients with advanced HIV infection with CD4 lymphocyte counts of < 200/ul.

Cryptococcal meningitis remains a major cause of HIV-related mortality worldwide with the largest burden of disease in sub-Saharan Africa, and southeast Asia<sup>3</sup>. Although there are case reports of cryptococcosis in immunocompetent hosts in recent years, presence of this infection should alert a

physician to look for any immunological incompetency. Apart from HIV/AIDS, several cases of AIDS like symptoms without HIV infection reported in the recent years have shown severe depletion of CD4 T lymphocytes predisposing these patients to severe opportunistic infections. These cases have been termed as Idiopathic CD4 lymphocytopenia (ICL) that apparently is not caused by any transmissible agent. It occurs without any detectable bias in age or sex, without any evidence of sexual transmission and with no specific endemicity. Recently a case of ICL presenting as disseminated tuberculosis, responding to anti-tubercular treatment has been published<sup>4</sup>.

Idiopathic CD4 lymphocytopenia was first defined in 1992 by the centres for disease control and prevention (CDC) as CD4 T-lymphocyte depletion (absolute CD4 T lymphocyte level < 300/ul or < 20% of total lymphocytes at a minimum of two separate time points with no serological evidence of HIV infection and the absence of any defined immunodeficiency or therapy associated with depressed levels of CD4 T cells<sup>2</sup>.

The aetiology and pathogenesis of ICL remains poorly understood and inadequately defined. The reduction in CD4 count may be due to decreased production, increased destruction or tissue sequestration or combination of any or all of these factors. The multifactorial pathogenesis with several proposed hypotheses are involvement of primitive bone marrow compartment due to diminished generation of T-cell precursors such as CD34+, CD38-DR+. The decreased availability of stem cell precursors contribute to depletion of CD4+ cells in these patients<sup>5</sup>. There are also evidences to suggest that in patients with ICL there is an overexpression of Fas/CD95, which is a member of the tumour necrosis family and can directly transduce an apoptotic death signal leading to increased apoptosis of T-cells in these patients<sup>6,7</sup>. Impaired early biochemical events of the CD3-TCR pathway like reduction in p56, lak and tyrosine activity, involved in the T-cell activity process may contribute to the reduced counts of the CD4+ cells in these patients<sup>8</sup>. There is defective production of cytokines such as TNF  $\alpha$  and IFN  $\gamma$  in ICL patients and serum levels of IL-7 are usually very high and found to have inverse correlation with CD4 count<sup>9</sup>. The high IL-7 levels may represent cytokine accumulation due to decreased IL-7 receptors alpha chain expression on T-cells (CD 127)<sup>10</sup>. The presence of CD4 T cell antibody in patients with ICL, signifies the role of autoimmune destruction of CD4+ cells in these patients<sup>11</sup>.

The clinical spectrum of ICL ranges from an asymptomatic laboratory abnormality to life-threatening complications that imitate the clinical course of AIDS patients. ICL is typically revealed by the emergence of opportunistic infection. The ICL syndrome can be complicated by many opportunistic

infections which are shown in Table I. Among these, cryptococcus is one of the most commonly described infections in the literature. Lymphocytopenia is frequently present in autoimmune diseases. However, patients with ICL are found to have increased risk for autoimmune diseases like SLE, antiphospholipid syndrome, autoimmune haemolytic anaemia, autoimmune thyroiditis and vasculitis mainly due to lack of self-recognition in the setting of lymphocytopenia induced T-cell proliferation.

Clinical differentiation of ICL with HIV infection is very difficult. In patients with ICL, serum immunoglobulin levels usually lie within or near to normal range, in contrast to elevated levels in HIV-infected patients. Moreover in ICL, patients have lower counts of CD8 and CD3 cells along with CD4 cells, implying a more generalised state of immunodeficiency while HIV patients have early increase of CD8 cells. In contrast to progressive decline of CD4 count in HIV infection, ICL patients may have spontaneous partial or complete reversal of lymphocytopenia, which is highly unusual for HIV.

The treatment of ICL mainly consists of prophylaxis and treatment of opportunistic infections. There should be a regular follow-up of the asymptomatic ICL patients immediately after establishing the diagnosis as most opportunistic infections have been described in the first month of the follow-up. Screening for lymphoma or HPV-related cervical or anal dysplasia may also be appropriate. Guidelines for patients with ICL are not available, and thus the current recommendations are based mainly on experience with HIV-infected patients only. As in HIV patients, prophylaxis against pneumocystis is recommended when CD4 T-cell counts fall below 200/uL. Cryptococcus as well as relapsing multisegmental herpes infection may require lifelong secondary prophylaxis<sup>12</sup>.

There is a continuous research going on in the field of therapy directed at increasing the CD4 counts in patients with ICL<sup>13</sup>. There are studies to suggest that IL-2 therapy can increase CD4 counts in patients with ICL<sup>14</sup>. Even after exhaustive research there are some grey areas that need to be addressed properly. Currently IFN- $\gamma$  and especially IL-7 are also being extensively studied<sup>15</sup>.

## Conclusion

Despite two decades of investigations, ICL still remains an enigma with uncertain pathogenesis, unknown prognosis and undefined treatment with heterogeneous presentations as some patients may remain asymptomatic, which others may develop life-threatening opportunistic infections or autoimmune conditions.

This case report emphasizes that any immunocompetent patient presenting with rare opportunistic infections should

be strongly suspected for idiopathic CD4 lymphocytopenia and there should be a meticulous search for the presence of other rare opportunistic infections. Patients should be managed accordingly with regular monitoring of the CD4 levels. Our case report also emphasizes the vast scope for research and more treatment options available in the field of therapy directed at increasing the CD4 levels in such patients. Further, studies of genetic basis and immunopathogenesis of this condition are the need of the day, so that targeted therapy for this devastating syndrome can be established to reduce morbidity and mortality.

## References

1. Jones GA, Nathwani D. Cryptococcal meningitis. *Br J Hosp Med* 1995; 54: 439-45.
2. Unexplained CD4+ T-lymphocyte depletion in persons without evident HIV infection – United States. *Morb Mortal Wkly Rep* 1992; 41: 541-5.
3. Park BJ, Wannemuehler KA, Marston BJ *et al.* Estimation of the current global burden of cryptococcal meningitis among persons living with HIV/AIDS. *AIDS* 2009; 23 (4): 525-30.
4. Ramalingam PK, Gayathri K, Santhakumar RPSP *et al.* Idiopathic CD4 Lymphocytopenia. *J Assoc Physicians Ind* 2016; 64 (5): 81-2.
5. Isgro A, Marziali M, Mezzaroma I *et al.* Bone marrow clonogenic capability, cytokine production and thymic output in patients with common variable immunodeficiency. *J Immunol* 2005; 174: 5074-81.
6. Laurence J, Mitra D, Steiner M *et al.* Apoptotic depletion of Cd4+ T-cells in idiopathic CD4+ T lymphocytopenia. *J Clin Invest* 1996; 97: 672-80.
7. Roger PM, Bernard-Pomier G, Counillon E *et al.* Over expression of Fas/CD95 and Fas-induced apoptosis in a patient with idiopathic CD4+ T lymphocytopenia. *Clin Infect Dis* 1999; 28: 1012-6.
8. Hubert P, Bergeron F, Grenot P *et al.* Deficiency of the CD3-TCR signal pathway in three patients with idiopathic CD4+ lymphocytopenia. *J Soc Biol* 1999; 193: 11-6.
9. Netea MG, Brouwer AF, Hoogendoorn EH *et al.* Two patients with cryptococcal meningitis and idiopathic CD4 lymphopenia: defective cytokine production and reversal by recombinant interferon  $\gamma$  therapy. *Clin Infect Dis* 2004; 39: e83-e87.
10. Zonios DI, Falloon J, Bennett JE *et al.* Idiopathic CD4+ lymphocytopenia: natural history and prognostic factors. *Blood* 2008; 112: 287-94.
11. Salit RB, Hankey KG, Yi R *et al.* Detection of CD4+ T-cell antibodies in a patient with idiopathic CD4 T lymphocytopenia and cryptococcal meningitis. *Brit J Haematol* 2007; 139: 133-7.
12. Walker UA, Warnatz K. Idiopathic CD4 lymphocytopenia. *Curr Opin Rheumatol* 2006; 18: 389-95.
13. Yilmaz-Demirdag Y, Wilson B, Lowery-Nordberg M *et al.* Interleukin-2 treatment for persistent cryptococcal meningitis in a child with idiopathic CD4 + T lymphocytopenia. *Allergy Asthma Proc* 2008; 29: 421-4.
14. Warnatz K, Draeger R, Schlesier M *et al.* Successful IL-2 therapy for relapsing herpes zoster infection in a patient with idiopathic CD4+ T lymphocytopenia. *Immunobiol* 2000; 202: 204-11.
15. Sheikh V, Porter BO, DerSimonian R *et al.* Administration of interleukin-7 increases CD4 T-cells in idiopathic CD4 lymphocytopenia. *Blood* 2016; 127 (8): 977-88.